

CASE REPORT

Expedited Correction of Significant Dentofacial Asymmetry Using a “Surgery First” Approach

CARLOS VILLEGAS, DDS
FLAVIO URIBE, DDS, MDS
JUNJI SUGAWARA, DDS, PHD
RAVINDRA NANDA, BDS, MDS, PHD

Symmetry is considered a hallmark of facial attractiveness.^{1,2} Skeletal asymmetries generally require surgical intervention to improve facial esthetics and correct any associated malocclusions. The classic approach involves a presurgical phase of orthodontics, during which dental compensations are eliminated, and a postsurgical phase to refine the occlusion. The presurgical phase can be lengthy, involving tooth decompensations that often exaggerate the existing dentofacial deformities.³

Skeletal anchorage now makes it possible to eliminate the presurgical orthodontic phase and to correct minor surgical inaccuracies and relapse tendencies after surgery. In addition to a significant reduction in treatment time, this approach offers immediate gratification in the correction of facial deformities,² which can translate into better patient compliance with elastic wear and appointments. Another reported advantage is the elimination of soft-tissue imbalances that might interfere with orthodontic tooth

movements.

This article describes a “surgery first” approach in a patient with complex dentofacial asymmetry and Class III malocclusion.

Diagnosis

A 20-year-old female presented with the chief complaints of facial asymmetry and underbite (Fig. 1). From a frontal view, she displayed significant mandibular asymmetry; the chin was deviated about 5mm to the right,



Dr. Villegas



Dr. Uribe



Dr. Sugawara



Dr. Nanda

Dr. Villegas is an Assistant Professor, Department of Orthodontics and Maxillofacial Surgery, University of CES, Medellín, Colombia. Dr. Uribe is an Assistant Professor and Program Director, Dr. Sugawara is a Visiting Professor, Division of Orthodontics, and Dr. Nanda is Professor and Head, Department of Craniofacial Sciences, Alumni Endowed Chair, School of Dental Medicine, University of Connecticut, Farmington, CT. E-mail Dr. Nanda at nanda@nso.uhc.edu.

Correction of Dentofacial Asymmetry Using a “Surgery First” Approach

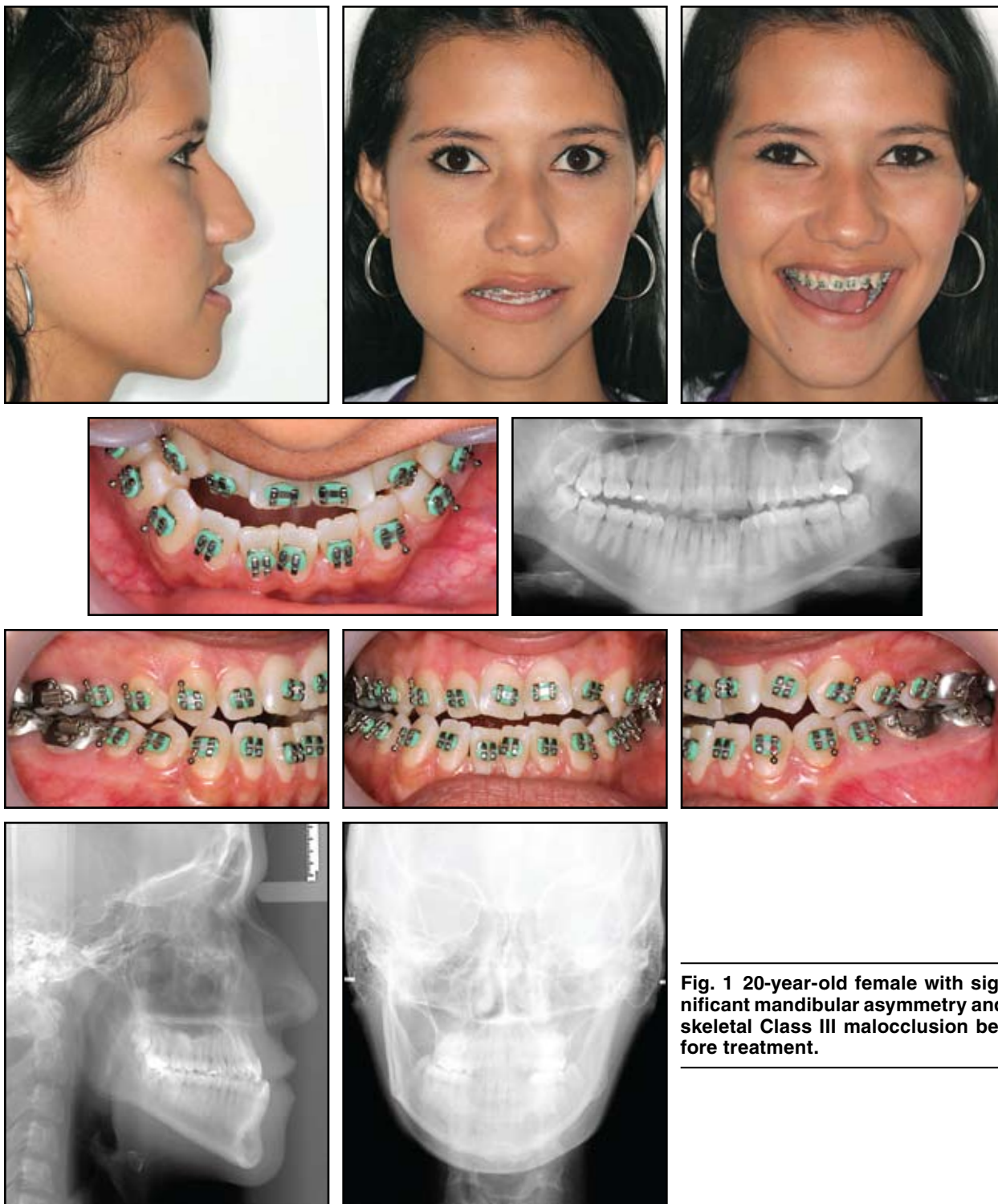

Fig. 1 20-year-old female with significant mandibular asymmetry and skeletal Class III malocclusion before treatment.

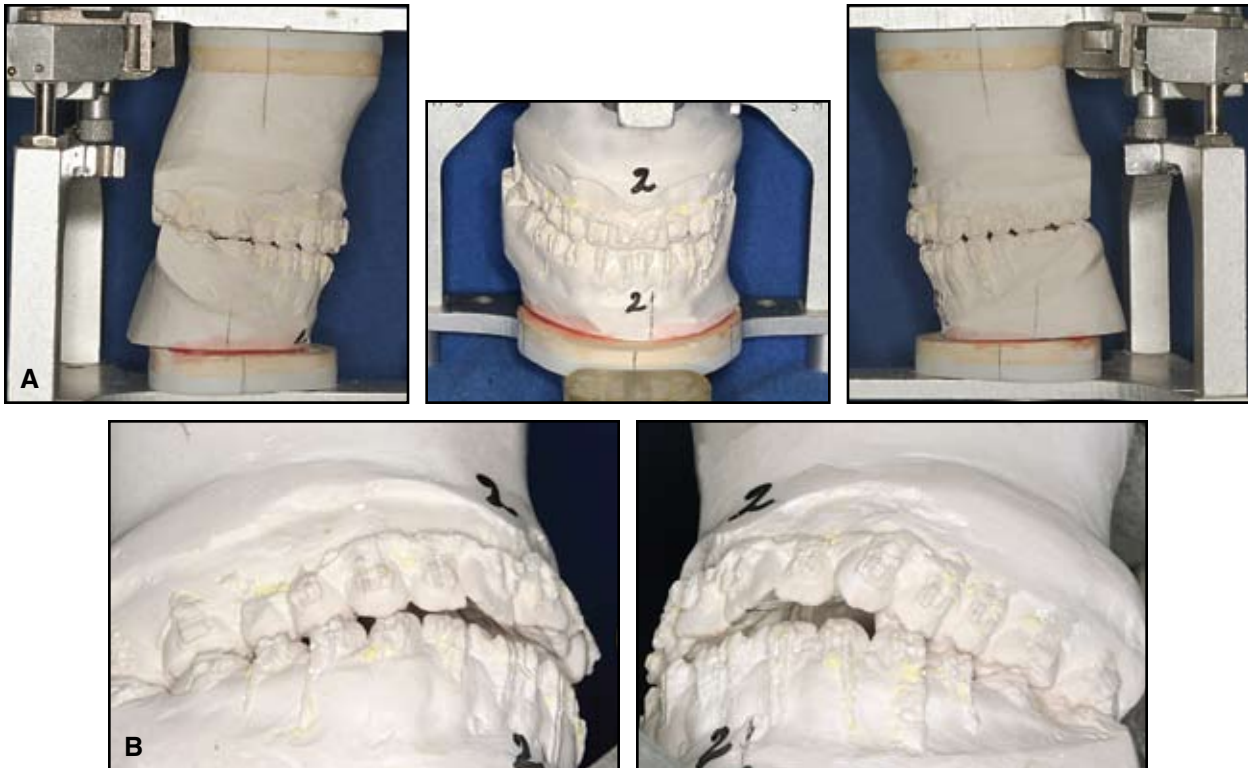


Fig. 2 A. Model surgery showing asymmetrical mandibular setbacks of 7mm on left and 3mm on right, with menton and lower dental midline moved 3mm left to match facial and maxillary dental midlines. **B.** Expected postsurgical Class II occlusion, intended to maintain maxillary incisor inclination.

but there was no vertical component to the asymmetry. She had a consonant smile with 80% incisor display, but an asymmetrical lower lip line with less animation on the right.

The maxillary dental midline was coincident with the cupid's bow, while the mandibular dental midline was deviated 5mm to the right. In the sagittal view, the patient had a slight concavity of the hard tissues due to a prognathic mandible. The soft-tissue profile was straight, however, because of deficient chin thickness. The lower lip was slightly protrusive, and there was no mentolabial fold.

The patient had a Class I molar occlusion on the right, a

full-cusp Class III occlusion on the left, and a negative overjet of 4mm, with moderate anterior crowding in both arches. The maxillary incisor inclination was ideal, while the mandibular incisors were slightly upright. A unilateral crossbite was noted on the right side, and there was a mild anterior open bite.

Because the patient was extremely self-conscious about her facial asymmetry, she was amenable to surgical options. She accepted a "surgery first" approach that would achieve an esthetic smile and normal occlusion while minimizing the time required in fixed appliances and addressing her main esthetic concern.

Surgical Plan

Although the patient had a slight paranasal deficiency, the maxillary anteroposterior position was adequate. Based on the etiology of the malocclusion, we decided on an asymmetrical single-jaw surgery, with the mandible set back 7mm on the left and 3mm on the right, to address both the prognathism and the asymmetry. In addition, an anteriorly sliding genioplasty would maintain soft-tissue convexity, reduce the lower lip protrusion, and accentuate the mentolabial fold (Fig. 2).

The postsurgical occlusion was planned to exhibit excessive overjet and an end-to-end Class II

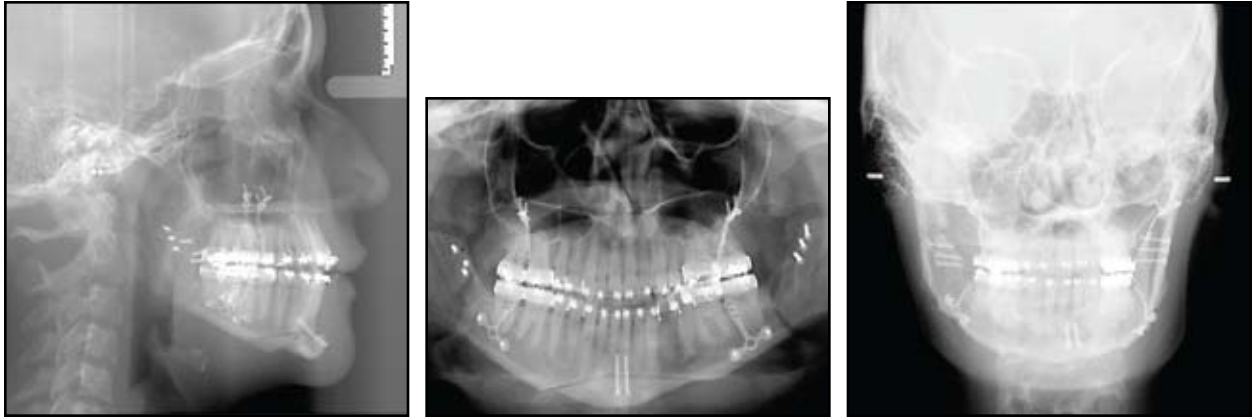


Fig. 3 Placement of four miniplates in infrazygomatic crest of maxilla and external oblique ridge of mandible during surgery.

relationship. The buccal segments would then be distalized into a Class I occlusion, using maxillary miniplates as anchorage, to create the space needed to align the maxillary anterior teeth without affecting the ideal incisor inclination. The excessive overjet would be resolved by labial movement of the lower incisors.

Treatment Progress

One week before orthognathic surgery, .022" preadjusted brackets were bonded, and bands were placed on the first and second molars. A bilateral sagittal split osteotomy was performed to achieve the required asymmetrical setback, accompanied by a sliding genioplasty with a 4mm advancement. All four third molars were extracted to avoid the need for later surgery.^{4,5} In addition, four miniplates were placed on the infrazygomatic crest of the maxilla and in the external oblique ridge of the mandible (Fig. 3).

After soft-tissue closure, .016" × .016" and .014" nickel titanium wires were inserted in the maxillary and mandibular arches, respectively, with the maxillary archwire bypassing the crowded central incisors and left lateral incisor (Fig. 4). Intermaxillary elastics were worn from the maxillary first premolars to the mandibular canines and from the maxillary miniplate to the mandibular canines.

Two weeks after surgery, the patient exhibited moderate swelling, but an .016" × .016" stainless steel maxillary archwire could still be tied in, again bypassing the central incisors and the left lateral incisor. An elastomeric chain was extended from the miniplate to the canine on the right side and from the miniplate to the first premolar on the left side (Fig. 5). Two weeks later, the elastomeric chains were replaced by nickel titanium coil springs.

Two months after surgery, the molars and canines were in Class I occlusion. Conveniently, a

slight space had opened between the maxillary right central and lateral incisors, and this was used to match the midlines.

Treatment Results

Seven months after surgery, the fixed appliances were removed. The final records showed good esthetic and occlusal results, and the superimpositions confirmed the achievement of all treatment objectives.

The miniplates were left in place for six months of retention. During this time, we evaluated the stability of the orthodontic treatment, and the miniplates could have been used if any post-operative orthodontic or surgical relapse had occurred. With no relapse evident, the miniplates were removed after six months (Fig. 6).

Discussion

Because orthodontic tooth movement generally has little ef-

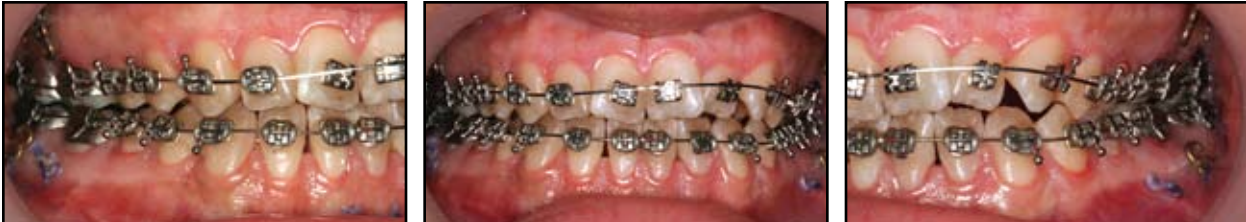

Fig. 4 .016" × .016" nickel titanium wire placed in maxillary arch, bypassing incisors to prevent flaring; .014" nickel titanium wire placed in mandibular arch for alignment.

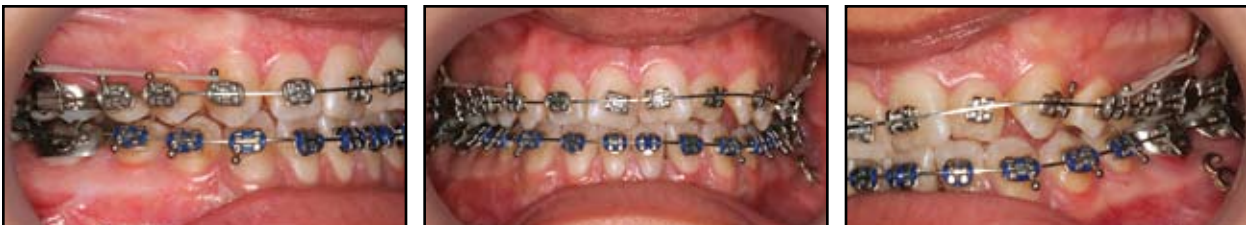
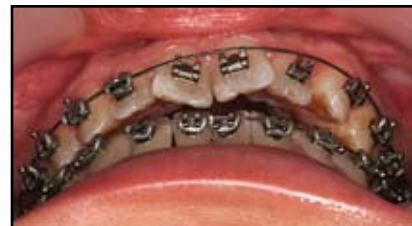
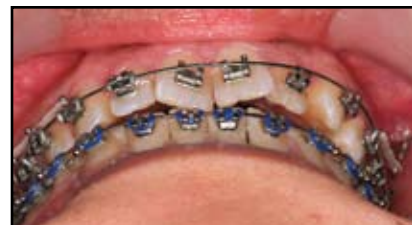Fig. 5 Distalization of maxillary buccal segments into Class I relationship, using anchorage from maxillary miniplates.



fect on extraoral soft-tissue esthetics, camouflage treatment alone cannot be relied on to rectify severe dentofacial asymmetries. Surgical correction becomes complicated, however, when the soft- and hard-tissue discrepancies do not match. In this patient, although the hard-tissue profile was concave, the soft tissues were straight. Correction of the malocclusion therefore required an asymmetrical setback with an advancing genioplasty.

The “surgery first” approach described by Nagasaka and colleagues has two significant advantages: immediate correction of soft-tissue deformities and reduced treatment time.⁶⁻⁸ In addition, the placement of four miniplates provides three-dimensional control for postsurgical correction of any relapse tendencies or slight discrepancies between the planned and actual surgical outcomes. If plates are inserted in all quadrants regardless of the surgical

procedure (one- or two-jaw), these vertical and anteroposterior adjustments in tooth position need not rely solely on elastics. Placing miniplates does increase the time required for surgery by an average 10-15 minutes per plate, but we have not encountered any intra- or postoperative complications with this surgical approach.

In contrast to the technique described by Nagasaka and colleagues, who placed passive stiff wires conforming to the maloc-

Correction of Dentofacial Asymmetry Using a "Surgery First" Approach

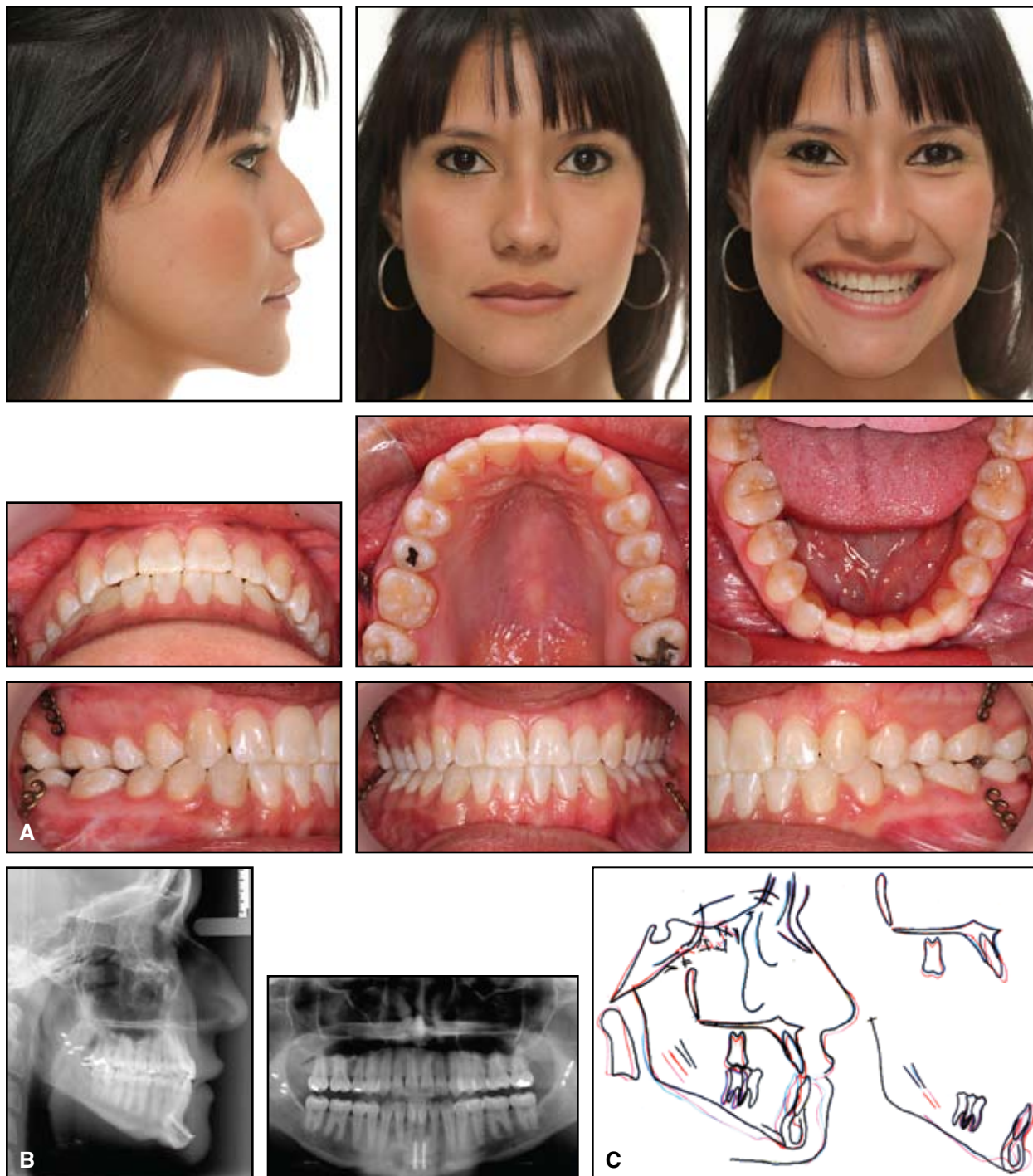


Fig. 6 A. Patient after seven months of treatment. **B.** Radiographs taken six months later, after removal of miniplates at end of retention period. **C.** Superimposition of cephalometric tracings before treatment (black), immediately after surgery (blue), and after six months of retention (red).

clusion,⁶ we inserted nickel titanium archwires after the soft tissues were sutured in the operating room. This method could expedite tooth movement by taking advantage of the increased cell turnover that occurs after mechanical alteration of bone.⁹ Such biological response has been noted with corticotomy-assisted tooth movement; bone turnover can also be accelerated in areas distant to the surgical site.¹⁰

In another departure from Nagasaka's approach, we did not use a splint to stabilize the occlusion after surgery. Model surgery indicated that the occlusion would be stable in a cusp-to-cusp relationship, and the maxillary teeth could then be distalized to relieve the anterior crowding while maintaining the incisor positions and inclination. The patient was delighted with the dramatic esthetic change achieved in such a short period of wearing fixed appliances.

Conclusion

The "surgery first" approach can be used to address complex dentofacial asymmetry, as shown in this case. Treatment time can be substantially reduced by eliminating the presurgical phase and taking advantage of increased bone turnover, which in turn can accelerate tooth movement.

ACKNOWLEDGMENTS: The authors thank Drs. Brett Holliday and Amirparviz Davoody for their collaboration on the manuscript.

REFERENCES

1. Bashour, M.: History and current concepts in the analysis of facial attractiveness, *Plast. Reconstr. Surg.* 118:741-756, 2006.
2. Thornhill, R. and Gangestad, S.W.: Facial attractiveness, *Trends Cogn. Sci.* 3:452-460, 1999.
3. Proffit, W.R. and White, R.P.: Combining surgery and orthodontics: Who does what, when? in *Contemporary Treatment of Dentofacial Deformity*, ed. W.R. Proffit, Mosby, St. Louis, 2003, pp. 245-267.
4. Mehra, P.; Castro, V.; Freitas, R.Z.; and Wolford, L.M.: Complications of the mandibular sagittal split ramus osteotomy associated with the presence or absence of third molars, *J. Oral Maxillofac. Surg.* 59:854-858, 2001.

5. Precious, D.S.; Lung, K.E.; Pynn, B.R.; and Goodday, R.H.: Presence of impacted teeth as a determining factor of unfavorable splits in 1256 sagittal-split osteotomies, *Oral Surg. Oral Med. Oral Pathol. Oral Radiol. Endod.* 85:362-365, 1998.
6. Nagasaka, H.; Sugawara, J.; Kawamura, H.; and Nanda, R.: "Surgery first" skeletal Class III correction using the Skeletal Anchorage System, *J. Clin. Orthod.* 43:97-105, 2009.
7. Brachvogel, P.; Berten, J.L.; and Hausamen, J.E.: [Surgery before orthodontic treatment: A concept for timing the combined therapy of skeletal dysgnathias], *Deutsche Zahn. Mund. Kieferheilk. Zentralb.* 79:557-563, 1991.
8. Tsuruda, H. and Miyamoto, Y.: None or minimum pre-operative orthodontic treatment for orthognathic surgery in answer to patient's request of immediate facial aspect change, *J. Jap. Soc. Aesth. Plast. Surg.* 25:79-86, 2003.
9. Frost, H.M.: The biology of fracture healing: An overview for clinicians, Part II, *Clin. Orthop. Relat. Res.* 248:294-309, 1989.
10. Mueller, M.; Schilling, T.; Minne, H.W.; and Ziegler, R.: A systemic acceleratory phenomenon (SAP) accompanies the regional acceleratory phenomenon (RAP) during healing of a bone defect in the rat, *J. Bone Miner. Res.* 6:401-410, 1991.